

See discussions, stats, and author profiles for this publication at: <https://www.researchgate.net/publication/320111932>

Pan-Aasian Consensus – Key recommendations for adapting the World congress of dermatology consensus on combination treatment with injectable fillers, toxins, and ultrasound devices...

Article in *Journal of Clinical and Aesthetic Dermatology* · August 2017

CITATIONS

5

READS

1,012

12 authors, including:



Chiranjiv Chhabra

6 PUBLICATIONS 21 CITATIONS

SEE PROFILE



Sabrina G Fabi

University of California, San Diego

102 PUBLICATIONS 1,113 CITATIONS

SEE PROFILE



Martina Kerscher

University of Hamburg

343 PUBLICATIONS 5,340 CITATIONS

SEE PROFILE



Atchima Suwanchinda

Mahidol University

17 PUBLICATIONS 144 CITATIONS

SEE PROFILE

Some of the authors of this publication are also working on these related projects:



Anatomical correlation of Aging Face for Filler and Toxin Injection [View project](#)



Eye-Tracking to evaluate face attractiveness after minimal-invasive treatment [View project](#)



ABSTRACT

BACKGROUND. The demand for minimally invasive aesthetic procedures has driven requests by physicians for guidance on their use in Asian patients, who have unique cultural preferences, social trends, and anatomy. However, few guidelines exist, particularly on combination treatment strategies for different facial shapes or indications such as the modification of face shapes to the “oval ideal.” Physicians must, therefore, apply Caucasian patient-optimized guidelines to their Asian patients.

METHODS. Eleven specialists developed a consensus on the use of botulinum toxin A (BoNT-A), calcium hydroxylapatite (CaHA) and hyaluronic acid (HA) fillers, and microfocused ultrasound with visualization (MFU-V) devices in Asian patients on upper-, middle-, and lower-face indications, including strategies to modify different facial shapes to the oval shape. Approval from 70 to 90 percent of all participants led to moderate consensus, while 90 percent agreement denoted a strong consensus. **RESULTS.** For early intervention/enhancement and restoration, most combination strategies are similar between Asian and Caucasian patients. Compared to Caucasian patients, however, beautification is a more common focus in Asian patients. The “ideal” oval facial shape can be created using different interventions depending on the patient’s baseline characteristics. **CONCLUSIONS.** Although treatments and treatment sequences for early intervention/enhancement and restoration for beautification in Asian patients are similar to those in Caucasian patients, different treatment strategies may be required.

KEYWORDS: Asian, consensus guidelines, combination treatment, fillers, botulinum toxin

CONSENSUS

PAN-ASIAN CONSENSUS— Key Recommendations for Adapting the World Congress of Dermatology Consensus on Combination Treatment with Injectable Fillers, Toxins, and Ultrasound Devices in Asian Patients

by YATES Y.Y. CHAO, MD; CHIRANJIV CHHABRA, MBBS, DVD; NIAMH CORDUFF, MBBS, FRACS; SABRINA GUILLEN FABI, MD; MARTINA KERSCHER, MD; STEPHANIE C.K. LAM, MBChB; TATJANA PAVICIC, MD; BERTHOLD RZANY, MD, ScM; PETER H.L. PENG, MD; ATCHIMA SUWANCHINDA, MD; FANG-WEN TSENG, MD; and KYLE K. SEO, MD, PhD

Dr. Chao is with Chao and Chiu Institute of Dermatology, Taipei, Taiwan; Dr. Chhabra is with Skin Alive Clinic, New Delhi, India; Dr. Corduff is with Cosmetic Refinement Clinic, Geelong, Australia; Dr. Fabi is with Cosmetic Laser Dermatology, San Diego, California, USA; Dr. Kerschler is with University of Hamburg, Hamburg, Germany; Dr. Lam is with Central Health Medical Practice, Hong Kong; Dr. Pavicic is in Private Practice for Dermatology and Aesthetics, Munich, Germany; Dr. Rzany is with RZANY & HUND, Berlin, Germany; Dr. Peng is with P-Skin Professional Clinic, Kaohsiung, Taiwan; Dr. Suwanchinda is with Medisci Biointegrative and Antiaging and Cosmetic Medical Center, Bangkok, Thailand; Dr. Tseng is with Milano Aesthetic Clinic, Taipei, Taiwan; and Dr. Seo is with Seoul National University College of Medicine and Modelo Clinic, Seoul, Korea.

J Clin Aesthet Dermatol. 2017;10(7):16–27

IN ORDER FOR PHYSICIANS TO EFFICIENTLY deliver optimal patient outcomes, contemporary aesthetic medicine now requires the harmonious combination of multiple aesthetic therapies. Current guidelines with instructive recommendations on the application of combination treatments focus predominantly on Caucasian patients.^{1–3} Few such guidelines are available for Asian patients; therefore, physicians must apply recommendations optimized

for Caucasian anatomies and aesthetic goals to Asian patients. Asian patients seek aesthetic intervention at a younger age, compared to Caucasians,⁴ and their requests typically focus on early intervention/enhancement, beautification,⁵ and the correction of facial deficits.⁶ In comparison, Caucasian patients typically seek restorative interventions for more severe, age-related problems. Physicians are inevitably faced with the challenge of effectively

FUNDING: No funding was provided for this study.

DISCLOSURES: Drs. Kerschler, Lam, Peng, Suwanchinda, and Tseng have no conflicts of interest relevant to the contents of this article. Dr. Rzany is a speaker and/or advisor for IPSEN and its affiliates, Galderma and Merz. Dr. Chhabra has no . Dr. Seo is a clinical investigator and/or consultant for Allergan, Merz Pharmaceuticals, Q-Med/Galderma, Medytox, LG Life Sciences, and Daewoong. Dr. Corduff is a speaker/advisor for Merz, Motiva, and Spiran. Dr. Fabi is a speaker, consultant, and investigator for Galderma, Merz, Allergan, and Valeant and is an investigator for Revance. Dr. Pavicic is a speaker and/or advisor for Merz, Galderma, Cynosure, Eucerin, Dermaceutic, and Ipsen. Dr. Chao is a speaker and/or advisor for Galderma, Merz, and Valeant.

AUTHOR CORRESPONDENCE: Yates Chao; Email: yateschao@gmail.com

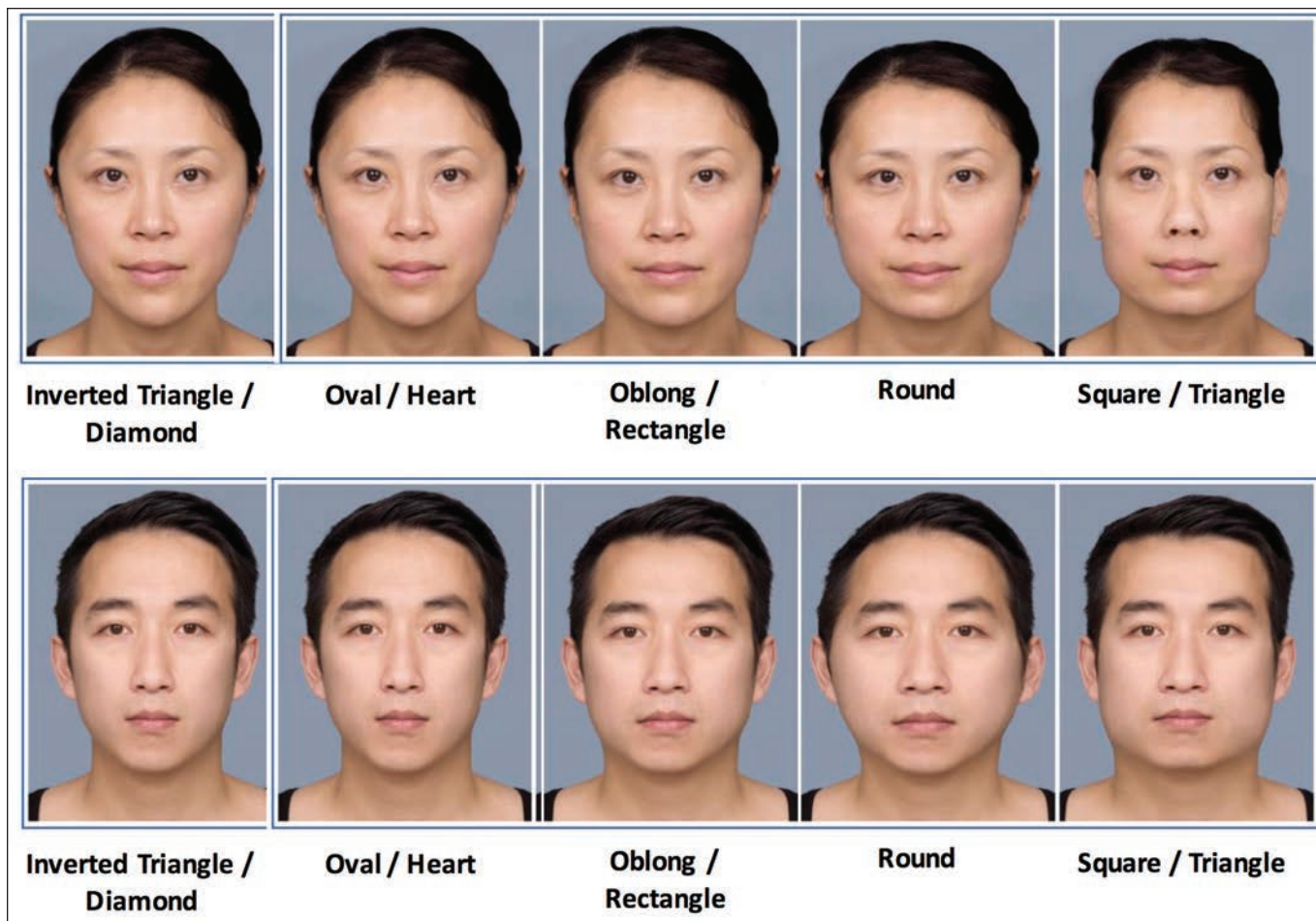


FIGURE 1. Common face shape categories

The face shape categories for women (top) and men (bottom). Five classical face shapes are widely recognized regardless of geography, age, or gender. The oval and heart are considered ideal for women. (Photos courtesy of Merz Pharmaceuticals GmbH.)

adapting nonoptimal treatment recommendations to Asian patients with very different physical presentations, issues, and expectations. This consensus aims to provide much-needed recommendations on aesthetic interventions and combination treatment algorithms for Asian patients, with a particular focus on the application of botulinum toxin A (BoNT-A), injectable fillers, and microfocused ultrasound with visualization (MFU-V).

CONSENSUS METHODOLOGY

Eleven physicians (“experts”) with experience in treating Asian patients were guided by a certified moderator to discuss combination therapy in Asian populations. The experts voted

on recommendations for early intervention/enhancement, restoration, and beautification and sought to achieve consensus on combination treatment strategies for the modification of different facial shapes (oval/heart, oblong/rectangular, round, square) to the ideal oval shape (Figure 1). Signed patient consent to publish all photos included in this article was obtained by the authors.

The recommendations focused on therapy combining BoNT-A (incobotulinumtoxinA, Xeomin[®], Merz Pharmaceuticals GmbH, Frankfurt am Main, Germany), calcium hydroxylapatite (CaHA, Radiesse[®], Merz North America, Inc., Raleigh, North Carolina, United States), hyaluronic acid fillers (HA, Belotero[®]

Intense, marketed as Fortélis Extra in Taiwan, and Belotero[®] Soft, marketed as Esthélis Soft in Taiwan; manufactured by Anteis S.A., Geneva, Switzerland, a wholly owned subsidiary of Merz Pharmaceuticals GmbH, Frankfurt, Germany), and MFU-V (Ultherapy[®], Ulthera Inc., Mesa, Arizona, United States).

The experts were from Hong Kong, Taiwan, South Korea, Thailand, India, Australia, Germany, and the United States, and had several years of working experience with all interventions (BoNT-A: average 4.8 years, range 1–10 years; HA: average 4.1 years, range 0.5–10 years; CaHA: average 5.3 years, range 1–8 years; MFU-V devices: average 2.5 years, range 0.5–5 years).

Before the meeting, the experts completed a

TABLE 1. Grading of voting for consensus statements

AGREEMENT LEVEL	CONSENSUS
100%	Absolute = "Recommend"
≥90%	Strong = "Suggest"
70–90%	Moderate
50–70%	Weak
≤50%	Disagreement

survey of their clinical experiences with these products to align their knowledge and focus subsequent discussions. Knowledge from a recently published consensus on combined methods in Caucasian patients directed the formulation of recommendations discussed in this document.¹

The experts first stated whether they agreed or disagreed with a recommendation. They then discussed their relevant personal clinical experiences and their survey responses. Experts without experience with a technology or topic in Asian patients abstained from voting. Any recommendation failing to achieve a strong or absolute consensus (agreement) was revised or refined, and voting was repeated. Agreement by all experts resulted in an absolute consensus (100%). A "strong" consensus required a minimum of 90-percent agreement or approval, "moderate" consensus required 70- to 90-percent agreement or approval, and "weak" consensus required 50- to 70-percent agreement or approval (Table 1).⁷ Two types of wording guided the voting process: "recommend" in cases where data were available and the level of consent was high or "suggest" when personal clinical experience led to a different perspective or less agreement.

For consistency, early intervention/enhancement were defined as treatments performed for prevention or restoration/rejuvenation and to improve or correct flaws and increase youthful appearance. Beautification interventions were defined as procedures performed for natural beautifying purposes (e.g., to reach the desired oval facial shape).

RESULTS

General recommendations. The experts largely agreed with general recommendations proposed for Asian patients; however, notable minor differences were found (Table 2).

Part 1: Combination treatment strategies for Asian patients— Specific indications. Upper face indications.

Interventions for upper face features discussed here included forehead volume deficiency with or without brow ptosis, forehead rhytides, lateral canthal lines, glabellar frown lines, temporalis hypertrophy, and hollows.

Forehead volume deficiency without brow ptosis. The experts unanimously agreed with the use of HA filler for early intervention/enhancement and restoration (absolute consensus, Table 3A). Concomitant treatment with BoNT-A for the frontalis and corrugator muscle could also be applied in order to prevent unevenness due to muscular activity. The use of a HA filler with projection capacity was recommended for Asian patients.

Forehead volume deficiency with brow ptosis. Asians may naturally lack brow bone contouring or have age-related drooping of the fat pad beneath the brows; therefore, filling of this area can lift brows and "open" the eyes. However, brow ptosis is not commonly treated in Asia. If present, volume deficiency is treated with HA, while eyebrow lifting is performed with BoNT-A.⁸ If only early intervention is required, HA treatment alone may be sufficient. BoNT-A treatment is only considered to be effective for hyperactive depressor muscles. Occasionally, BoNT-A can be combined with energy-based devices to treat hypertonic/hyperkinetic supraciliary muscles. If performed on the same day as MFU-V, BoNT-A should be applied immediately after MFU-V treatment (Table 3B). Filling beneath the brows can be done two weeks prior to MFU-V or immediately after MFU-V if done on the same day.

Forehead rhytides. For early intervention/enhancement, the experts suggested using BoNT-A followed by HA fillers

(Table 3C), both of which may be applied within the same treatment session. For restoration, energy devices can be used superficially before BoNT-A and filler. To prevent further weakening of the frontalis or if volume deficiency is visible (with or without ptosis), HA could be applied first. Eyebrow position (whether ptotic) may be naturally lower in Asians and can impact the rhytide.⁹ To preserve brow position, low-dose or diluted BoNT-A was suggested for forehead rhytides, particularly if treatments for early intervention/enhancement are sufficient.¹⁰

Lateral canthal lines. Lateral canthal lines are not usually deep in Asian patients, but in cases of severe volume loss, HA can be combined with BoNT-A treatments. Absolute consensus was reached on the recommendations to use only BoNT-A for early intervention and BoNT-A followed by MFU-V and/or HA fillers (to treat loose skin) for restoration.

Glabellar frown lines. While BoNT-A treatment was only suggested for early intervention/enhancement, BoNT-A treatment for restoration received a unanimous recommendation (Table 3E). The experts agreed that restoration should begin with a series of BoNT-A treatments, and, if no sufficient improvement is observed, HA fillers should then be carefully injected into the superficial dermis.

Temporal hollowing and temporalis hypertrophy. Temple hollowing in Asian patients requires more contouring than in Caucasian patients.¹¹ For early intervention/enhancement of temporal hollows, low doses of HA filler were recommended. For beautification, the combination of HA and/or CaHA was recommended (Table 3F). For temporalis hypertrophy, BoNT-A rather than fillers was recommended for all aesthetic goals (Table 3G).

Mid-face indications. Mid-face indications discussed included nose shaping, cheek volume, and nasolabial folds (Table 4).

Cheek volume deficiency (anteromedial, submalar, and subzygomatic). Weak consensus was given for the use of MFU-V first to reposition

TABLE 2. Summary of recommendations from the Vancouver Consensus on Combination Treatment Strategies for Caucasian Patients: Combination treatment strategies for Asian patients

No.	STATEMENT FOR CONSIDERATION	CONSEN-	ADDITIONAL SUGGESTIONS
A. General recommendations			
1	Thoroughly assess anatomical structure and age-related changes to the bone, fat, ligament, muscle, and skin.	100%	none
2	Discuss treatment goals and ensure that the patient understands the progressive nature of the aging process.	100%	none
3	Formulate an individualized treatment plan.	100%	
4	Discuss cost and estimate the most effective treatment(s) and the sequence of procedures and/or treatments.	100%	none
5	In patients with limited financial means, focus on treating areas that will have the greatest impact.	91%	none
6	Avoid over-treatment and unnatural results or, conversely, under-treatment and suboptimal results.	100%	none
7	Schedule appropriate follow-up visits to assess and document results.	100%	none
B. Topicals			
1	Use broad-spectrum ultraviolet (UV) protection of at least 30 sun protection factor (SPF) daily.	100%	
2	Add a moisturizing agent with restorative additives for improvements in hydration, fine lines, laxity, dyschromia, and to brighten the skin.	100%	Perform skin analysis with dermatologist and recommend other modalities, (e.g., laser).
C. Sequence of multiple treatments in one area			
1	If possible, allow 1–2 weeks after each procedure to allow for resolution of local side effects and assess the results.	100%	First follow-up visit should not be earlier than 2 weeks after treatment, regardless of the emergence of unwanted effects.
	Refinement of recommendations by experts: If possible, allow the appropriate time after each procedure to allow for resolution of local side effects and assess the results.	100%	
2	BoNT and HA and/or CaHA fillers may be performed on the same day in either sequence.	91%	To avoid toxin spreading beyond the treatment area, BoNT-A can be done as second-line treatment following filler (HA and/or CaHA).
3	For combination therapy with multiple agents on the same day, Ulthera is performed prior to injectable agents as long as there is no significant tissue swelling.	91%	Combination therapy can be done on the same day if toxins are applied to a different anatomical region (e.g., cheeks versus forehead). To do within the same region, a 1–2 week wait is recommended.
	Refinement of recommendation by experts: For combination therapy with multiple agents on the same day, Ulthera is performed prior to injectable agents.	82%	







superficial fat pads as an early intervention/enhancement in the treatment of cheek volume deficiencies that were not affected by laxity (Table 4B). To address volume loss, fillers (HA or CaHA) were suggested (Table 4A–C) for early intervention/enhancement. For cheeks suffering laxity, MFU-V treatment immediately before HA and/or CaHA fillers was suggested for same-day

restoration treatments, as published in previous consensus statements.¹ For early combination interventions, MFU-V (to tighten skin) and/or HA (to volumize) treatments were suggested. As CaHA filler has volumization and skin-tightening benefits, it can be used alone to treat skin laxity or in combination with MFU-V. HA and/or CaHA fillers were recommended for anteromedial,

submalar, and subzygomatic cheek areas; however, only advanced users should attempt CaHA fillers in the anteromedial cheek (Table 4A–C).

Nose shaping. The use of HA fillers and/or CaHA before BoNT-A (if indicated; Table 4D) was recommended for nose shaping, which was considered a beautification procedure rather than

TABLE 3. Consensus on combination treatment strategies for the upper face in Asian patients

AESTHETIC DEFICIENCY AND INDICATION	RECOMMENDATIONS			ADDITIONAL COMMENTS
	EARLY INTERVENTION/ ENHANCEMENT	RESTORATION	BEAUTIFICATION	
A. Volume deficiency in forehead without brow ptosis 	HA fillers only*	HA + BoNT-A if applicable	HA + BoNT-A (if applicable)*	Asian foreheads rarely show sagging, but patients with brow ptosis might have naturally low brows. As more volume is lost, the brow becomes more ptotic but without sagging.
B. Volume deficiency in forehead with brow ptosis 	BoNT-A to lift the brow*	1. BoNT-A to lift the brow 2. MFU-V (Ultherapy) and/or HA and/or CaHA fillers	Not applicable – no voting	This is not typically requested in Korean and Taiwanese patients. In Thailand, early intervention only requires toxin while restoration requires all treatments.
C. Forehead rhytides 	1. BoNT-A* 2. HA fillers*	1. BoNT-A (unless contraindicated) 2. HA fillers	Not applicable – no voting	None
D. Lateral canthal lines 	Only BoNT-A	M-FUV (Ultherapy) and/or HA fillers	Not applicable – no voting	None
E. Glabellar frown lines 	Only BoNT-A*	1. BoNT-A 2. HA fillers	Not applicable – no voting	To perform both procedures on the same day for restoration, Dr. Seo would ideally start with BoNT-A but both BoNT-A and HA fillers are required for restoration; ideally, doctors would wait 1–2 weeks before performing filler injections.
F. Temporal hollows 	HA fillers	HA and/or CaHA (Radiesse)*†	HA and/or CaHA (Radiesse)	None
G. Temporalis hypertrophy	BoNT-A*			30–50U/side of Xeomin can be used for early intervention

Recommendations with an asterisk (*) received strong consensus (at least 90% agreement). Numbered treatments indicate the order in which the procedures should be performed.

†Procedure or technique is only recommended for experienced users.

HA= Hyaluronic acid. BoNT-A= Bontulinum Toxin Type A. CaHA=Calcium hydroxylapatite. MFU-V= Microfocused ultrasound with visualization

an early intervention/ enhancement or restoration intervention. The high risk of vascular compromise in this area requires that interventions involving CaHA be performed only by skilled injectors.

Nasolabial fold (NLF). The NLF was differentiated into upper and lower folds due to the potential for vascular compromise.¹² Correction through lateral facial revolumization should always be attempted first. For the upper fold, only HA fillers for early intervention/enhancement and HA fillers and/or CaHA fillers for restoration (Table 4E) were recommended.

Lower-face indications. Lower-face indications discussed included perioral rhytides, lip fullness, marionette lines, chin, mental crease, and jawline (Table 5).




Perioral rhytides. The use of BoNT-A before HA fillers for early intervention/enhancement and BoNT-A with HA fillers before MFU-V for the restoration of perioral rhytides (Table 5A) were recommended. Readers are urged to refer to the previous consensus publication for recommended treatment timeline.¹ Several experts suggested using BoNT-A only for early intervention/

enhancement or if “mimetic activity” was pronounced.

Lip fullness/enhancement. Lip enhancement or shape change would be considered a beautification procedure in patients with sufficient lip volume (Table 5B). While CaHA is contraindicated for this indication, HA is recommended.

Marionette lines. While some experts agreed that early intervention/enhancement required BoNT-A, others suggested using MFU-V to minimize jowl fat pad protrusion or combining

TABLE 4. Consensus on combination treatment strategies for the mid-face in Asian patients

AESTHETIC DEFICIENCY AND INDICATION	RECOMMENDATIONS			ADDITIONAL COMMENTS
	EARLY INTERVENTION/ ENHANCEMENT	RESTORATION	BEAUTIFICATION	
A. Anteromedial cheek volume deficiency 	<i>HA and/or CaHA fillers (Radiesse)</i>			CaHA (Radiesse) should only be used by advanced operators for this indication
B. Submalar cheek volume deficiency 	<i>HA and/or CaHA fillers (Radiesse)</i>	Combination of fillers and/or M-FUV (Ultherapy)*	Not applicable – no voting	Moderate consensus (70%) was also received for the use of HA and/or CaHA fillers followed by M-FUV (Ultherapy), although this order is performed only if there is skin laxity. Weak consensus (40%) was received for the use of M-FUV (Ultherapy) followed by HA and/or CaHA fillers. Depending on the degree of submalar volume deficiency and laxity, performing M-FUV (Ultherapy) first may reposition fat in the treated area; therefore, less filler will be required subsequently.
C. Subzygomatic cheek volume deficiency	<i>HA and/or CaHA (Radiesse)</i>			None
D. Nose shaping 	No voting	No voting	1. <i>HA fillers and/or CaHA (Radiesse)</i> 2. <i>BoNT-A (if indicated)</i>	Radiesse should only be used by advanced operators for this indication
E. Nasolabial folds (NLF)	<i>HA fillers only</i>	<i>HA fillers and/or CaHA (Radiesse)</i>	Not applicable – no voting	Radiesse in the upper part of the fold should be avoided Geographical differences exist for this indication (see main text)

Recommendations shown in *italics* have received total consensus of 100% agreement given by the experts, while those indicated with an asterisk (*) received strong consensus (at least 90% agreement). Numbered treatments indicate the order in which the procedures should be performed.

HA= Hyaluronic acid. BoNT-A= Bontulinum Toxin Type A. CaHA=Calcium hydroxylapatite. MFU-V= Microfocused ultrasound with visualization

BoNT-A with fillers for restoration. HA and/or CaHA should be applied over the prejowl sulcus following mid-face restoration interventions (Table 5C).

Mentalis. BoNT-A may be utilized only if mimetic activity was observed, and first line treatment with toxin was recommended for early intervention/enhancement and restoration (Table 5E).

Jawline. CaHA, high in elasticity and viscosity, is ideal for jawline creation. For beautification, the masseter or platysma, but

not the jaw, should be treated with toxin, while filler should be used to sculpt different shapes and increase bone definition (Table 5F).

Masseter hypertrophy. The use of BoNT-A for all interventions was recommended (Table 5G). Toxin dose is a critical consideration.^{13,14} Toxin denervation without concomitant prejowl/chin augmentation can result in jowl fat sagging; hence, combination treatments are recommended. For early intervention/enhancement and beautification, most patients may require only BoNT-A for the

masseter. However, older patients with prominent jowls and submalar and subzygoma depressions may require concurrent filler augmentation of the cheek and chin or MFU-V for lifting.

Part 2: Combination treatment strategies for Asian patients— Modifying face shapes to achieve the “oval ideal.” The experts unanimously agreed that the oval or heart facial shape was an aesthetic goal of Asian patients and that combination treatments were recommended to achieve this because single interventions were unlikely to produce

TABLE 5. Consensus on combination treatment strategies for the lower face in Asian patients

AESTHETIC DEFICIENCY AND INDICATION	RECOMMENDATIONS			ADDITIONAL COMMENTS
	EARLY INTERVENTION/ ENHANCEMENT	RESTORATION	BEAUTIFICATION	
A. Perioral rhytides	1. <i>BoNT-A</i> 2. <i>HA fillers</i>	1. <i>BoNT-A and HA fillers</i> 2. <i>M-FUV (Ultherapy)</i>	Not applicable – no voting	None
B. Lip enhancement 	1. <i>HA fillers</i> 2. <i>Additional effects with BoNT-A and/or M-FUV (Ultherapy) (for lip eversion)</i>			Bruising may be a consideration
C. Marionette lines 	1. <i>BoNT-A and/or HA and/or CaHA fillers</i> 2. <i>M-FUV (Ultherapy) (if indicated)</i>	1. <i>HA and/or CaHA fillers in the midface and jawline AND BoNT-A</i> 2. <i>M-FUV (Ultherapy)</i>	Not applicable – no voting	Experts advise against injecting too deeply or into submucosa as this may cause nodules, especially if multiple injections with large volumes are performed
D. Chin volume loss 	1. <i>HA and/or CaHA fillers</i> 2. <i>BoNT-A (if indicated)</i>	<i>BoNT-A and HA and/or CaHA fillers</i>	1. <i>HA and/or CaHA fillers*</i> 2. <i>BoNT-A (if indicated)*</i>	None
E. Mental crease 	<i>BoNT-A only below the mentalis</i>	<i>BoNT-A and HA and/or CaHA fillers (combination)</i>	Not applicable – no voting	Mental crease is rarely treated in Asian patients. BoNT-A should be injected below the mental crease as early intervention to weaken the contraction of the mentalis
F. Jawline (lateral line of jaw) 	No consensus overall: Moderate (63.6%): <i>M-FUV (Ultherapy) then BoNT-A (only if indicated)</i> Low (45.45%): <i>BoNT-A (only if indicated) then M-FUV (Ultherapy)</i>	<i>Radiesse and/or HA fillers, followed by BoNT-A (if indicated) and M-FUV (Ultherapy)</i> Moderate consensus (63.6%): <i>Fillers first followed by Ultherapy and BoNT-A</i>	Moderate consensus (77.78%): <i>Radiesse and/or HA fillers, followed by BoNT-A (if indicated) and M-FUV (Ultherapy)</i>	Consensus was not reached for early intervention of the jawline because BoNT-A may be placed intradermally, may be used for platysma band treatment, or for the masseter. Therefore, this lack of clarity led to the inability to reach an agreement.
G. Masseter hypertrophy	<i>BoNT-A</i>			Doses are crucial to prevent concurrent sagging

Recommendations shown in *italics* have received total consensus of 100% agreement given by the experts, while those indicated with an asterisk (*) received strong consensus (at least 90% agreement). Numbered treatments indicate the order in which the procedures should be performed.

HA= Hyaluronic acid. BoNT-A= Bontulinum Toxin Type A. CaHA=Calcium hydroxylapatite. MFU-V= Microfocused ultrasound with visualization.

significant changes. This consensus focused on the treatments and treatment sequences, as these may be influenced by patient factors, such as cultural preferences and personal finances.

Treatment suggestions for patients with the ideal oval/heart face shape. For beautification or enhancement of facial features that are less prominent in Asians, only specific concerns should be addressed. For example, filler can be injected into the medial

cheek or pyriform aperture for anterior projection of the nose or concavities. For more heart-shaped faces, augmentation of the medial malar area may be necessary for oval shaping and to increase anterior projection (Figure 2).

Treatment suggestions for patients with oblong/rectangular face shape. Oblong/rectangular faces contain a longer mandibular bone that pulls fat downward and flattens the central area. This requires lower

face narrowing and smoothing, midface/anterior area projection, temple and forehead smoothing, and nose and lip augmentation (Figure 3).

Treatment suggestions for patients with round face shape. To bring the round face closer to the oval shape, the masseter should be reshaped and contoured via BoNT-A injection to slim or narrow the lower face, and midface anterior projection should be improved through chin elongation (Figure 4).

Treatment suggestions for patients with square face shape. Due to the magnitude of corrections required, square faces need the most interventions (Figure 5).

DISCUSSION

The experts agreed that cultural and country-specific preferences determine aesthetic goals and must be included as part of aesthetic treatment strategies.

East Asians do not generally find square, thin faces attractive but prefer softer, more oval-shaped faces for both sexes.¹⁵⁻¹⁷ While similarities do exist and can be applied to all Asian nationalities, some critical differences in preferences are apparent, especially in what is considered congenital and what is considered aesthetically appealing. Korean faces, for example, have fuller, chubbier cheeks with shorter faces,¹⁷ while Chinese faces have relatively narrow, slim faces with longer jaws, fuller lips, and narrower noses.^{18,19}

In the treatment of Korean women for forehead volume deficiencies with brow ptosis, overly arched or lifted brows and lateral orbital rims must be avoided, as these are perceived as exaggerated and aggressive.^{20,21} Physicians, therefore, use MFU-V treatments for brow ptosis in these patients. Chinese patients often request filler augmentation in the temporal area, regardless of whether they have significant temporal hollowing and temporalis hypertrophy, as the area is thought to represent fortune in Chinese culture.

Treatment recommendations for the NLF vary among Asian countries. Some physicians consider the upper NLF to be a natural curve rather than a flaw and will avoid overtreatment here, whereas others use MFU-V and inverse contraction of the nasolabial fat pad to lift the midface area. To treat masseter hypertrophy, Taiwanese physicians address the entire face rather than just the affected area, while Thai physicians use a lower dose of BoNT-A for masseter restoration alongside other

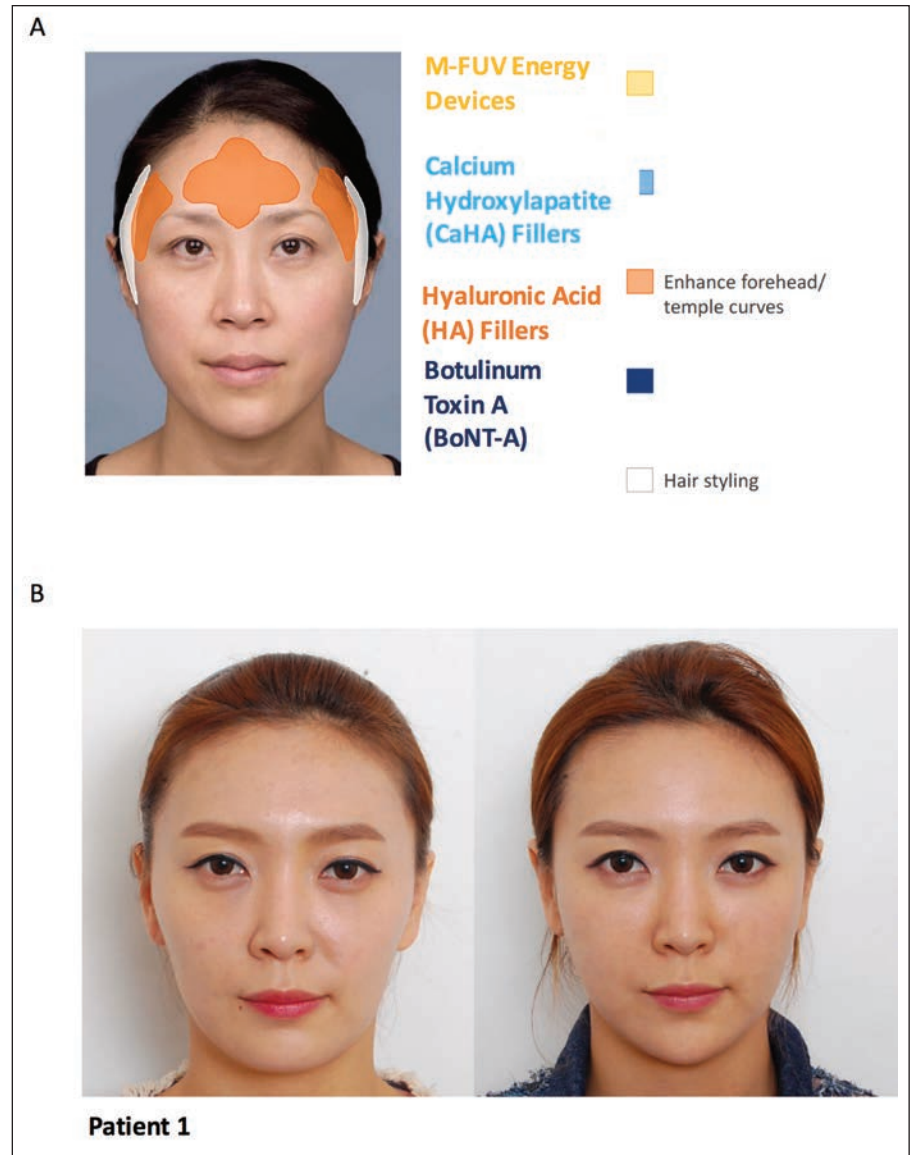

FIGURE 2. Treatment recommendations for the already ideal oval/heart shape

A) HA fillers can be applied for forehead augmentation and in the temples to increase the convexity of the curvature and create fullness and contouring here, as well as in the cheeks, to improve contours. Hairstyling can be used to narrow transverse widths over the cheekbones (photo courtesy of Dr. Yates Chao); B) Patient 1 received BoNT-A for the masseter several months prior to the photo being taken (left), which shows an exaggerated subzygomatic depression, aggravated zygomatic prominence, and a blunt chin. For oval shaping and face slimming, 1mL of filler was used per side for volumization of the subzygomatic depression and the anterior chin (right) (photos courtesy of Dr. Kyle Seo).

interventions for excessive sagging.

Some aesthetic preference commonalities exist. For example, due to unattractive or extreme images in the media, Asian patients refrain from lip plumping interventions. Asian chins tend to be smaller and recessed,^{22,23} resulting in age-related and congenital

deficiencies. Therefore, unlike Caucasians, Asians seek treatment for chin volume loss, rather than for chin projection.²⁴ Most Korean patients find longer faces unappealing.²⁵ Thus, while small-chin volumization requires fillers, Korean physicians do not usually perform chin volume augmentation.

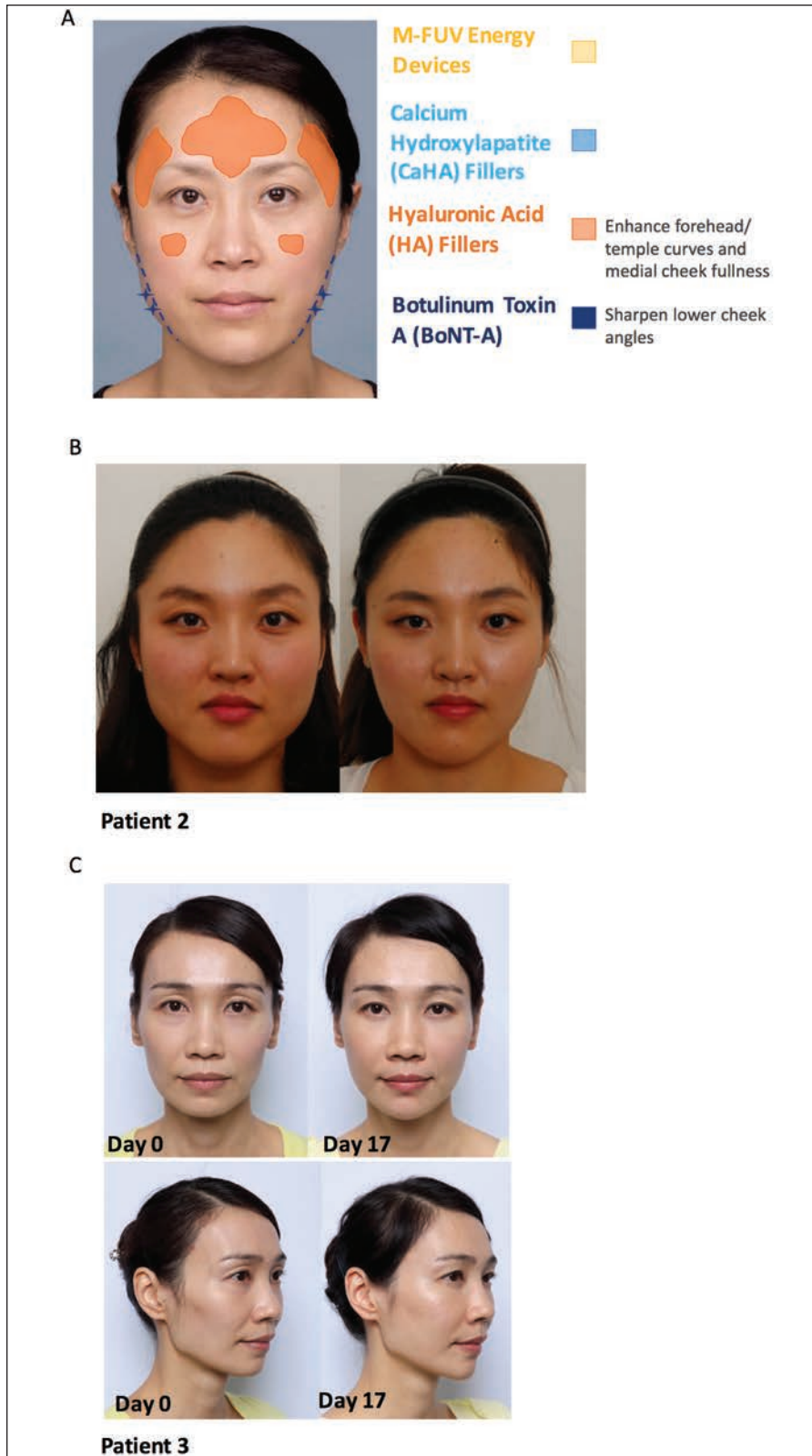


FIGURE 3. Treatment recommendations to bring the oblong/rectangular face closer to the ideal oval shape

A) Examples of beautification interventions on the oblong face (photo courtesy of Dr. Yates Chao); B) Patient 2 received toxin treatment for the masseter and temporalis (photo courtesy of Dr. Kyle Seo); C) Patient 3 shown at different viewing angles, before HA and CaHA filler treatment (top left and bottom left), with visible curve sculpting and contouring effects after 17 days (top right and bottom right) (photos courtesy of Dr. FW Tseng).

Aging-related bone recession and fat pad atrophy also affect treatment strategy.²⁶ Elderly patients may display chin irregularities caused by the mentalis muscle contracting onto atrophied bone. If this volume loss is age-related, the mentalis muscle will contract into this void²⁷ and require combination treatment. Age-related subzygomatic volume deficiency and atrophy²⁸ necessitate concurrent restorative interventions. Interestingly, subzygomatic depressions unrelated to laxity are frequently treated in young, East Asian women, together with oval-face shaping and a reduction of subzygomatic prominence.^{29,30}

Sex-determined goals also exist, particularly for beautification of the jawline. Asian men prefer straight, defined jaws but not broad or square jaws (in contrast to Caucasians).³¹ Jawline reduction and definition are frequently requested by Asian women;³² mandibular angle augmentation is more common than toxin treatment in Korea.^{33,34} To create a more defined jawline in Taiwanese men, MFU-V, toxin, and filler treatments are administered, as toxin alone is ineffective. These distinctions suggest that Taiwanese and Korean patients have different aesthetic goals for the jawline (Table 5F).

CONCLUSION AND FUTURE DIRECTIONS

To our knowledge, this is the first description of the aesthetic treatments required to achieve facial changes considered “ideal” for the Asian patient. It is not our intention to provide detailed treatment instructions, which can be found elsewhere.¹

Our current recommendations for combined interventions in Asian patients complement previous work^{1,35} by providing granular recommendations for early intervention/enhancement, restoration, or beautification treatments in Asians.

The experts in this current consensus displayed a high level of agreement with World Congress of Dermatology Consensus statements, demonstrating that the goals of beautification and treatment strategies using minimally

invasive technologies are actually similar between Caucasian and Asian patients. However, the indications, filler types, and dosages of botulinum toxin are factors that must be customized to the specificities of Asian faces.

The recognition and understanding of facial shapes is near universal but often focuses on the oval facial shape.^{36–39} In reality, ethnicity and societal preferences influence patient preferences.⁴⁰ Therefore, this consensus provides some guidance on the procedures necessary for the modification of nonideal face shapes to the oval ideal in individual patients. Combination treatments should be used holistically to reduce widths, angularity, and masculine features and to enhance feminization, three-dimensional projection, and contours in women. Ethnicity-determined congenital deficiencies and cultural biases should be respected and carefully considered during patient selection, counselling, and the formulation of optimal treatment plans. For the first time, this document establishes consensus recommendations and clinical guidance for physicians who wish to treat Asian patients more effectively and with optimal outcomes using defined combined interventions.

REFERENCES

1. Carruthers J, Burgess C, Day D, et al. Consensus recommendations for combined aesthetic interventions in the face using botulinum toxin, fillers, and energy-based devices. *Dermatol Surg.* 2016;42(5):586–597.
2. Sundaram H, Liew S, Signorini M, et al. Global Aesthetics Consensus Group. Global aesthetics consensus: hyaluronic acid fillers and botulinum toxin type A—recommendations for combined treatment and optimizing outcomes in diverse patient populations. *Plast Reconstr Surg.* 2016;137(5):1410–1423.
3. Wu WT, Liew S, Chan HH, et al. Asian Facial Aesthetics Expert Consensus Group. Consensus on current injectable treatment strategies in the Asian face. *Aesthetic Plast Surg.* 2016;40(2):202–214.
4. Liew S, Wu WT, Chan HH, et al. Consensus on




FIGURE 4. Beautification of the round face to bring it closer to the oval shape

A) Treatment recommendations for the round face (photo courtesy of Dr. Yates Chao); B) Patient 4 received BoNT for the masseter and filler for chin augmentation (photos courtesy of Dr. Yates Chao); C) Patient 5 also received filler for the subzygoma (posterior cheek) (photos courtesy of Dr. Kyle Seo).

- changing trends, attitudes, and concepts of Asian beauty. *Aesthetic Plast Surg.* 2015 Sep 25. [Epub ahead of print]
5. Weng CJ. Oriental upper blepharoplasty. *Semin Plast Surg.* 2009;23(1):5–15.
6. Liew S. Ethnic and gender considerations in the use of facial injectables: Asian patients. *Plast Reconstr Surg.* 2015;136(5 Suppl):225–275.
7. German Association of the Scientific Medical Societies (AWMF)—Standing Guidelines Commission. *AWMF Guidance Manual and Rules for Guideline Development, 1st ed.* 2012. English version. http://www.awmf.org/fileadmin/user_upload/Leitlinien/AWMF-Regelwerk/AWMF-Guidance_2013.pdf. Accessed November 26, 2015.
8. Young SM, Lim LH, Seah LL, et al. Prospective audit of ptosis surgery at the Singapore National Eye Centre: two-year results. *Ophthalmol Plast Reconstr Surg.* 2013;29(6):446–453.
9. Rhee SC, Woo KS, Kwon B. Biometric study of eyelid shape and dimensions of different races with references to beauty. *Aesthetic Plast Surg.* 2012;36(5):1236–1245.
10. Wu WT. Microbotox of the lower face and neck: evolution of a personal technique and its clinical effects. *Plast Reconstr Surg.* 2015;136(5 Suppl):925–1005.
11. Watanabe K, Miyagi H, Tsurukiri K. Augmentation of temporal area by insertion of silicone plate under the temporal fascia. *Ann Plast Surg.* 1984;13(4):309–319.
12. Beleznyay K, Humphrey S, Carruthers JD, Carruthers A. Vascular compromise from soft tissue augmentation: experience with 12 cases and recommendations for optimal outcomes. *J Clin Aesthet Dermatol.* 2014;7(9):37–43.

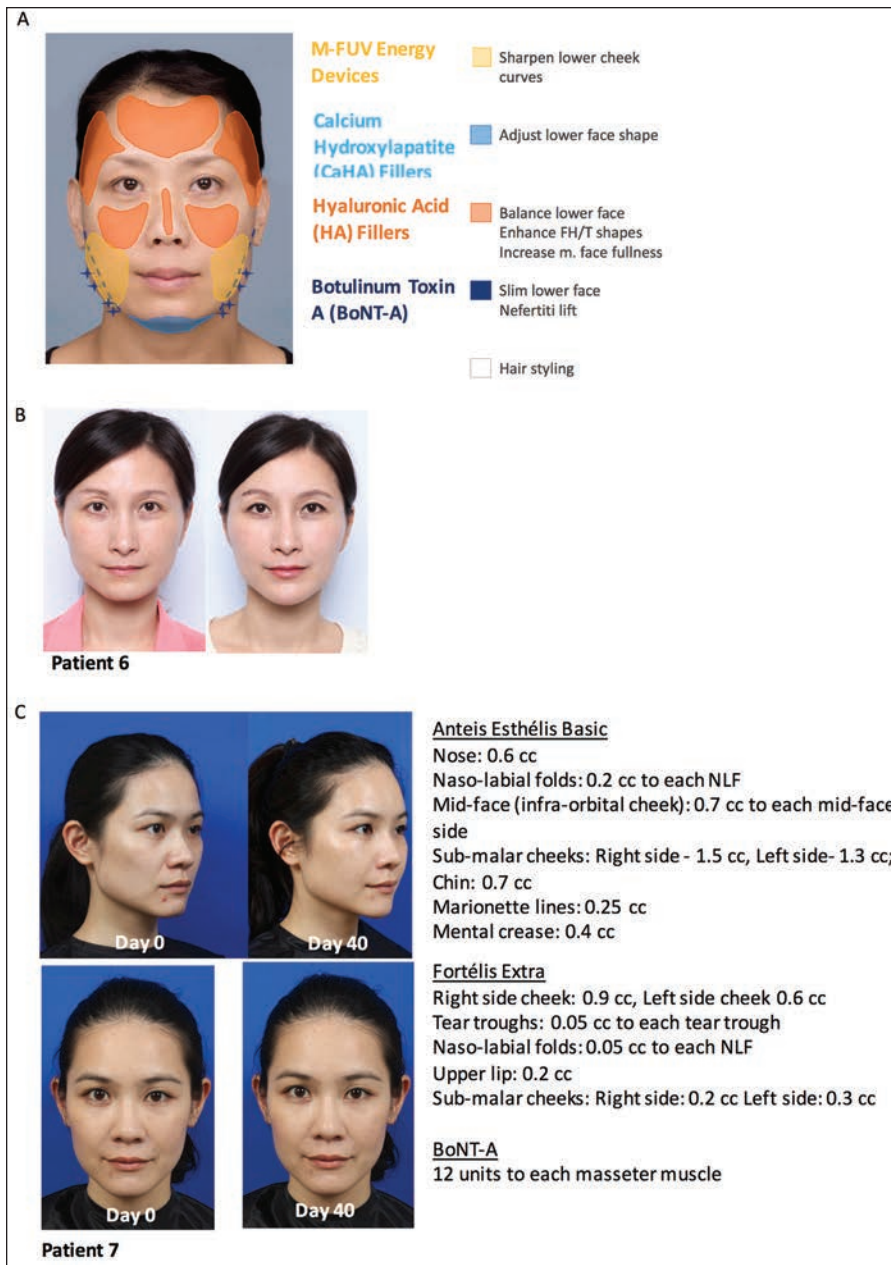


FIGURE 5. Treatment recommendations to bring the square face closer to the ideal oval shape

A) To modify a square face to an oval shape, HA fillers can be used to increase facial projection, enhance contours at the forehead and temples, and increase fullness. BoNT-A can be applied for jawline slimming and to create a Nefertiti lift, while CaHA fillers can be injected into the chin for contouring and projection. M-FUV devices can then be used to tighten the lower cheeks and sharpen angles (photo courtesy of Dr. Yates Chao); B) Patient 6, example of square to oval shape modification (photo courtesy of Dr. Yates Chao); C) Patient 7 before treatment (left and day 0 photos) and 40 days after BoNT-A injection to the masseter, with obvious masseter reduction. Treatment details are listed (photo courtesy of Dr. FW Tseng).

13. Ganceviciene R, Liakou AI, Theodoridis A, et al. Skin anti-aging strategies. *Dermatoendocrinol.* 2012;4(3):308–319.
14. Ahn KY, Park MY, Park DH, Han DG. Botulinum toxin A for the treatment of facial hyperkinetic wrinkle lines in Koreans. *Plast Reconstr Surg.* 2000;105(2):778–784.
15. Li X, Hsu Y, Hu J, et al. Comprehensive consideration and design for treatment of square face. *J Oral Maxillofac Surg.* 2013;71(10):1761.e1–14.
16. Mu X. Experience in East Asian facial recontouring: reduction malarplasty and mandibular reshaping. *Arch Facial Plast Surg.* 2010;12(4):222–229.
17. Lee JS, Kim HK, Kim YW. Anthropometric analysis of the attractive and normal faces in Korean female. *J Korean Soc Plast Reconstr Surg.* 2004;31(4):526–531.
18. Zhao Q, Zhou R, Zhang X, et al. Morphological quantitative criteria and aesthetic evaluation of eight female Han face types. *Aesthetic Plast Surg.* 2013;37(2):445–453.
19. Wu F, Li J, He H, et al. Soft-tissue facial characteristics of attractive Chinese men compared to normal men. *Int J Clin Exp Med.* 2015;8(5):7977–7982.
20. Kim BW, Park GH, Yun WJ, et al. Adverse events associated with botulinum toxin injection: a multidepartment, retrospective study of 5310 treatments administered to 1819 patients. *J Dermatolog Treat.* 2014;25(4):331–336.
21. Lam SM. Aesthetic strategies for the aging Asian face. *Facial Plast Surg Clin North Am.* 2007;15(3):283–291.
22. Shirakabe Y, Suzuki Y, Lam SM. A new paradigm for the aging Asian face. *Aesthetic Plast Surg.* 2003;27(5):397–402.
23. Hwang WS, Hur MS, Hu KS, et al. Surface anatomy of the lip elevator muscles for the treatment of gummy smile using botulinum toxin. *Angle Orthod.* 2009;79(1):70–77.
24. Lee TS, Kim HY, Kim TH, et al. Contouring of the lower face by a novel method of narrowing and lengthening genioplasty. *Plast Reconstr Surg.* 2014;133(3):274e–282e.
25. Kim TG, Lee JH, Cho YK. Inverted V-shape osteotomy with central strip resection: a simultaneous narrowing and vertical reduction genioplasty. *Plast Reconstr Surg Glob Open.* 2014;2(10):e227.
26. Coleman SR, Grover R. The anatomy of the aging face: volume loss and changes in 3-dimensional topography. *Aesthet Surg J.* 2006;26(15):S4–9.

27. Rohrich RJ, Pessa JE. The anatomy and clinical implications of perioral submuscular fat. *Plast Reconstr Surg.* 2009;124(1):266–271.
28. Buckingham ED, Glasgold R, Kontis T, et al. Volume management of the middle third-lower orbit/midface. *Facial Plast Surg.* 2015;31(1):55–69.
29. Lee HY, Yang HJ, Cho YN. Minimally invasive zygoma reduction. *Plast Reconstr Surg.* 2006;117(6):1972–1979.
30. Lee JG, Park YW. Intraoral approach for reduction malarplasty: a simple method. *Plast Reconstr Surg.* 2003;111(1):453–460.
31. Lee HY, Yang HJ, Cho YN. Minimally invasive mandible reduction using Lee’s Rasp & Saw. *Aesthetic Plast Surg.* 2007;31(2):201–205.
32. Lee TS, Kim HY, Kim T, et al. Importance of the chin in achieving a feminine lower face: narrowing the chin by the “mini V-line” surgery. *J Craniofac Surg.* 2014;25(6):2180–2183.
33. Kim NH, Chung JH, Park RH, Park JB. The use of botulinum toxin type A in aesthetic mandibular contouring. *Plast Reconstr Surg.* 2005;115(3):919–930.
34. Jin H. Misconceptions about mandible reduction procedures. *Aesthetic Plast Surg.* 2005;29(4):317–324.
35. Rho NK, Chang YY, Chao YY, et al. Consensus recommendations for optimal augmentation of the Asian face with hyaluronic acid and calcium hydroxylapatite fillers. *Plast Reconstr Surg.* 2015;136(5):940–956.
36. Farhadian JA, Bloom BS, Brauer JA. Male aesthetics: a review of facial anatomy and pertinent clinical implications. *J Drugs Dermatol.* 2015;14(9):1029–1034.
37. Li J, Hsu Y, Khadka A, et al. Contouring of a square jaw on a short face by narrowing and sliding genioplasty combined with mandibular outer cortex osteotomy in orientals. *Plast Reconstr Surg.* 2011;127(5):2083–2092.
38. Mitteroecker P, Windhager S, Müller GB, Schaefer K. The morphometrics of “masculinity” in human faces. *PLoS One.* 2015;10(2):e0118374.
39. Pedrosa VO, França FM, Flório FM, Basting RT. Study of the morpho-dimensional relationship between the maxillary central incisors and the face. *Braz Oral Res.* 2011;25(3):210–216.
40. Li D, Xu H, Xu L, et al. The aesthetic proportion index of facial contour surgery. *J Craniofac Surg.* 2015;26(2):586–589. 